

Simultaneous Maxillary and Mandibular Brown Tumors in Secondary Hyperparathyroidism: A Case Report

Bijan Movahedian*, Seyed Mohammad Razavi**, Darioush Hashemini***, Majid Rezaei***

ABSTRACT

Hyperparathyroidism (HPT) is a disease, which results from increased secretion of parathyroid hormone (PTH). Primary HPT results from autonomous hyperplasia or a tumor in parathyroid and secondary HPT is usually associated with decreased calcium level due to chronic renal disease. Brown tumors have been seen occasionally at the terminal stages of HPT. A case of 19-year-old man with history of end-stage renal disease (ESRD) demonstrating two expansive lesions in jaws is reported here. PTH and alkaline phosphatase (ALP) were extremely high and consequently, a diagnosis of secondary HPT was established. Contrary to the typical secondary HPT, the patient was normocalcemic. Computed tomography scan showed mixed radiolucent-radioopaque pattern of lesions and ossifications were significant. Surgical excision was carried out and histology revealed presence of fibro-endothelial connective tissue with broad areas of osteoids and numerous multinucleated giant cells, as seen in cases of brown tumors.

Keywords: Alkaline phosphatase, brown tumors, hyperparathyroidism.

Received: May 2008

Accepted: July 2008

Dent Res J 2008; 5(1): 41-45

Introduction

Hyperparathyroidism (HPT) is a disease in which there may be a complex of biochemical, anatomic and clinical abnormalities resulting from increased secretion of parathyroid hormone (PTH). It may occur in primary, secondary and tertiary forms.¹ Primary HPT results from autonomous hyperplasia or tumor, usually an adenoma.² Secondary HPT develops in response to chronic low levels of calcium usually associated with chronic renal disease.³ Incidence of HPT in chronic renal failure differs from 18% after one year on dialysis to 92% after more than 2 years.⁴ Occasionally, parathyroid tumors develop after longstanding secondary HPT, known as tertiary HPT.¹ Brown tumors represent the terminal stages of bone remodeling process in HPT.³ Of course brown tumors are uncommon in secondary HPT^{5,6} and extremely rare in normocalcemic hyperparathyroidism patients.⁷ Only a few cases of maxillary brown tumors in children and

adolescents with secondary hyperparathyroidism have been previously reported.⁸ This is a report of a 19-year-old case of secondary HPT with normal serum calcium level and unusual multiple peripheral manifestations including maxillary and mandibular findings.

Case report

The patient was a 19-year-old man referred to the oral and maxillofacial surgery clinic at Al-Zahra University Hospital of Isfahan University of Medical Sciences in August 2007. His chief complaint was intraoral swelling of upper and lower jaws. Review of past medical history revealed end-stage renal disease (ESRD). When he was 9-year-old, he'd been admitted for lower extremities, abdominal and facial edema in addition to hematuria. Consequently, he was diagnosed with chronic progressive renal failure. After six years of medical

*Assistant Professor, Department of Oral and Maxillofacial Surgery and Torabinejad Dental Research Center, School of Dentistry, Isfahan University of Medical Sciences, Isfahan, Iran.

**Assistant Professor, Department of Oral and Maxillofacial Pathology and Torabinejad Dental Research Center, School of Dentistry, Isfahan University of Medical Sciences, Isfahan, Iran.

***Clinical Resident, Department of Oral and Maxillofacial Surgery, School of Dentistry, Isfahan University of Medical Sciences, Isfahan, Iran.

Correspondence to: Bijan Movahedian, Department of Oral and Maxillofacial Surgery and Torabinejad Dental Research Center, School of Dentistry, Isfahan University of Medical Sciences, Isfahan, Iran. E-mail: b_movahedian@dnt.mui.ac.ir

therapy, he underwent a surgery for setting an arteriovenous fistula (AVF), followed by a 4-year course of dialysis. Subacute bacterial endocarditis was also remarkable in his profile. Other members of family were healthy. For the past six months, he had noticed a painless swelling affecting the anterior mandible followed by the second swelling in left side of maxilla, two months later in the pre-molar region. The mandibular lesion extended towards the lingual vestibule and measured approximately 35 mm in diameter (figure 1). The maxillary lesion was smaller and enlarged 20 mm toward the palate (figure 2). They were red-pink colored with occasional bleeding, which involved the adjacent teeth resulted in considerable mobility especially in mandibular lesion. Considering previous lab tests, it was very likely to be a secondary HPT. Therefore, further evaluation of PTH, calcium, phosphorus, alkaline phosphatase (ALP), blood urea nitrogen (BUN) and creatinine was ordered. PTH (2208 pg/ml, normal range = 12-70 pg/ml) and ALP (6366 U/L, normal range = 80-360 U/L) were extremely high and as a result, a diagnosis of secondary HPT was established. Contrary to the typical secondary HPT, the patient was normocalcemic (calcium = 8.8 mg/dl, normal range = 8.2-10.6 mg/dl). BUN, creatinine and phosphorus were within normal limits. Panoramic view showed generalized loss of lamina dura, which is expectable in these patients. Besides, two ill-defined lesions were apparent in anterior part of both jaws. Computerized tomography scan of these regions demonstrated mixed radiolucent-radiopaque lesions with expansion of cortical plates. The amount of ossification in maxillary lesion was significant and formed an onion skin pattern (figures 3). Based on clinical findings and patient's history, our initial differential diagnosis included central giant cell granuloma (CGCG), aneurismal bone cyst, ameloblastoma and fibrous dysplasia. All of these lesions have almost similar age distribution, clinical features and radiographic manifestation. CGCG is more common in the anterior part of the jaws. Most CGCGs are asymptomatic with gradual painless bony enlargement. Aneurismal bone cysts, mostly are diagnosed in mandible than in maxilla, are more frequent in posterior jaws. Besides, the most common clinical presentation is a bony swelling of rapid onset along with some degree of pain. More than 90% of ameloblastomas occur in posterior body and ramus of man-

dible. Fibrous dysplasia has a classic radiographic pattern of "ground glass" opacification. The diagnosis of brown tumor seemed extremely likely given the history of renal failure, high level of PTH and ALP, suggesting a secondary HPT. Therefore, regarding the functional problems for patient, surgical excision as an excisional biopsy and treatment was considered. Maxillary and mandibular lesions were removed by surgical excision and curettage. Specimens were analyzed histopathologically. Microscopic evaluation showed fibro-endothelial connective tissue with broad areas of osteoids peripherally lined by active osteoblasts. Increased activity of osteoclasts was seen. Fibroblasts were seen in place of resorbed trabeculae. Multinuclear giant cells spread throughout the lesion. There was multifocal fibrosis of bone marrow space (figures 4 and 5).

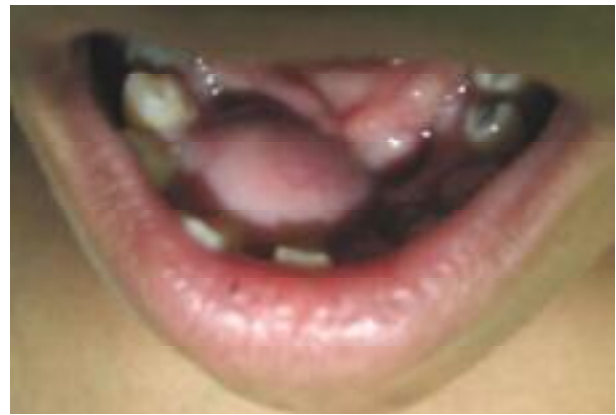

Figure 1. Clinical feature of mandibular lesion

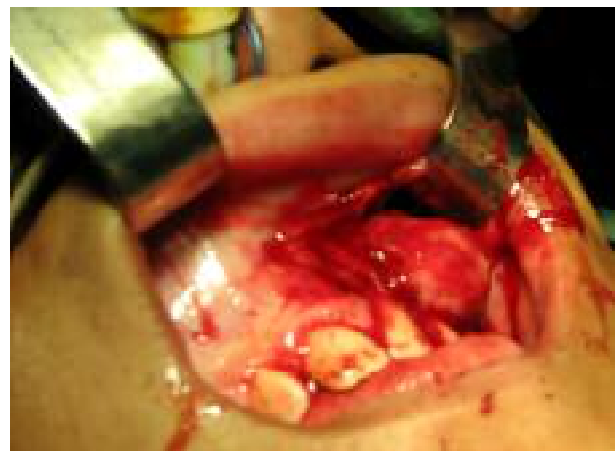

Figure 2. Intra operative view of maxillary lesion

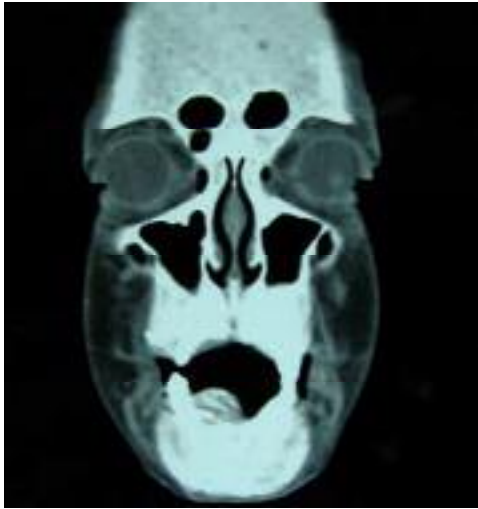


Figure 3. Computerized tomography image of lesion

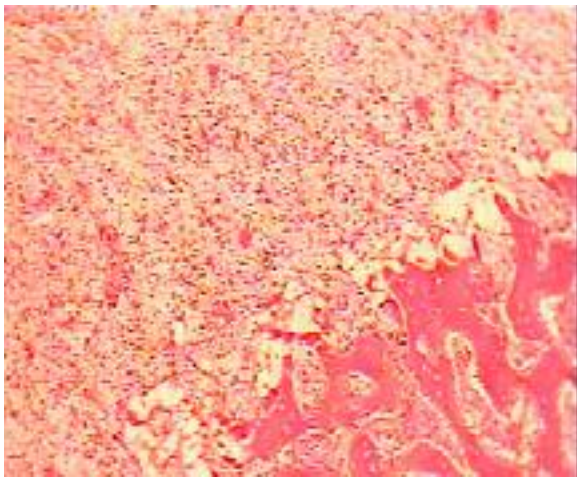


Figure 4. Neoformed bone formation in right site and multinuclear giant cells in left site (H&E stain, magnification X100).

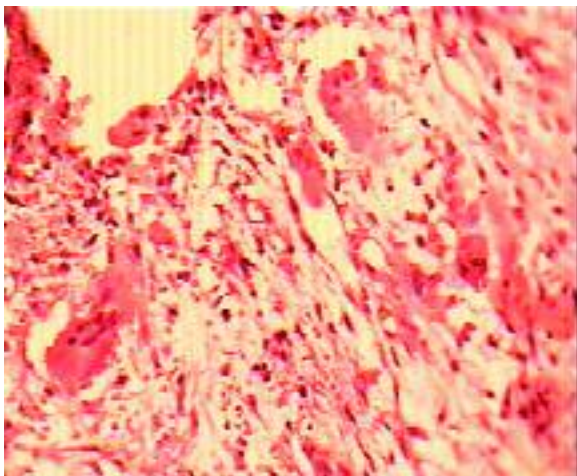


Figure 5. Multinuclear giant cells are prominent (H&E stain, magnification X400)

Discussion

Many skeletal changes may be accompanied by HPT. One of these changes is called Brown tumor. Prevalence of brown tumor is about 0.1%, more common in persons older than fifty years and more frequent in mandible than in maxilla. Contrary to our patient, simultaneous presence of maxillary and mandibular lesions is completely rare. It is three times more common in women than in men.⁹ However, some authors indicated that brown tumors are present in less than 5% of primary HPT and about 1.5% of secondary HPT patients.^{5,10-14} Except in ESRD, brown tumors are rarely reported in other conditions resulting to secondary hyperparathyroidism like rickets, anticonvulsant medications and malabsorption.¹⁵ Brown tumor is not a neoplastic lesion, but a kind of giant cell lesion (GCL) and named by its friable red-brown appearance mass.¹¹ This feature results from vascularity, hemorrhage and deposits of hemosiderin. Histologically, GCLs are non-encapsulated and consist of fibrous connective tissue, with an important proliferation of fibroblasts and multinucleated giant cells containing variable numbers of nuclei.¹ Like other GCLs such as CGCG, aneurismal bone cyst and cherubism, brown tumor exhibits slow growth and painless gradual enlargement,¹⁶ as our case did. Brown tumors involve the ribs, clavicle, pelvis and mandible more than other sites.¹⁷ Clinically significant lesions in the jaws are rare.⁸ Although Wood, Goaz¹ and Neville et al.³ implied that these lesions are most common in jaws, other literatures^{10,12,18,19} do not agree with them. Furthermore, some others reported that maxillary involvement is extremely rare.^{13,17,20} Radiographically, brown tumor appears as a well-defined unilocular to multilocular radiolucency. Since they are secondary to HPT, radiographic manifestations of HPT such as general rarefaction of the jaws, generalized loss of lamina dura around teeth and subperiosteal erosion of phalanges must be noticed as well.³ In our case, because of the high levels of ossification, the onion-skin pattern could be seen radiographically. Vascular granulation tissue with numerous multinucleated osteoclast-type giant cells is a typical histopathologic view of GCLs, like brown tumor or CGCG.^{11,12,16,19,21} As CGCG and Brown tumor are identical histopathologically, clinical investigation is important to differentiate between them. HPT, calcium and phosphorus level disturbance and increased serum ALP and PTH are helpful to diag-

nose a brown tumor. Hypercalcemia and hypophosphatemia are present in primary HPT while hypocalcemia and hyperphosphatemia are seen in secondary HPT.¹ As reported by Krause et al.⁸ brown tumor is extremely rare in normocalcemic HPT patients. However, in our case, HPT secondary to chronic renal failure didn't affect the level of calcium (normocalcemic HPT). Secondary HPT is managed by the means of hemodialysis or by renal transplantation. Significant bone disease may be prevented or diminished medically by calcium carbonate and vitamin D.¹¹ It's generally accepted that treatment of brown tumor should start with treatment of underlying HPT and if persisted after this primary treatment, enucleation and curettage should be added.^{4,11,17,19,22} Some clinicians have excised brown tumors before or concurrent with parathyroid anomalies.^{7,23,24} In rare occasions, radiotherapy or chemotherapy may be indicated. Other authors initially treat this lesion with systemic corticosteroids and, when it reduces its size, they remove it by surgical excision.²¹ We believe that the protocol for management of these lesions depends on the clinical significance. If the lesion results in some functional problems, as it usually does not regress medically, we recommend the surgical excision in addition to treatment of secondary HPT (surgically or medically). However, in case of no functional limitations, it's better to do medical therapy, hoping for probable regression and then surgical excision, if needed.

References

1. Wood NK, Goaz PW. Differential Diagnosis of Oral and Maxillofacial Lesions. 5th ed. St. Louis: Mosby; 1997.p. 393-6.
2. Cotran RS, Kumar V, Collins T, Robbins SL. Robbins pathologic basis of disease. 6th sub ed. Philadelphia: W.B. Saunders Company; 1999.p. 1148-51.
3. Neville B, Damm DD, Allen CM, Bouquot J, Neville BW. Oral & Maxillofacial Pathology. 2nd ed. Philadelphia: W.B Saunders; 2002.p. 724-6.
4. Okada H, Davies JE, Yamamoto H. Brown tumor of the maxilla in a patient with secondary hyperparathyroidism: a case study involving immunohistochemistry and electron microscopy. J Oral Maxillofac Surg 2000; 58(2): 233-8.
5. Mergenthaler HG, Fink M, Sauer H, Bartl R, Wilmanns W. Multiple brown tumors in a patient with nutritional secondary hyperparathyroidism. Klin Wochenschr 1989; 67(1): 42-6.
6. Pecovnik BB, Kavalari R. Brown tumor in association with secondary hyperparathyroidism. A case report and review of the literature. Am J Nephrol 1998; 18(5): 460-3.
7. Cebesoy O, Karakok M, Arpacioğlu O, Baltacı ET. Brown tumor with atypical localization in a normocalcemic patient. Arch Orthop Trauma Surg 2007; 127(7): 577-80.
8. Krause I, Eisenstein B, Davidovits M, Cleper R, Tobar A, Calderon S. Maxillomandibular brown tumor—a rare complication of chronic renal failure. Pediatr Nephrol 2000; 14(6): 499-501.
9. Keyser JS, Postma GN. Brown tumor of the mandible. Am J Otolaryngol 1996; 17(6): 407-10.
10. Tarrass F, Ayad A, Benjelloun M, Anabi A, Ramdani B, Benghanem MG, et al. Cauda equina compression revealing brown tumor of the spine in a long-term hemodialysis patient. Joint Bone Spine 2006; 73(6): 748-50.
11. Triantafyllidou K, Zouloumis L, Karakinaris G, Kalimeras E, Iordanidis F. Brown tumors of the jaws associated with primary or secondary hyperparathyroidism. A clinical study and review of the literature. Am J Otolaryngol 2006; 27(4): 281-6.
12. Franco M, Bendini JC, Albano L, Barrillon D, Casuto E, Bracco J. Radiographic follow-up of a phalangeal brown tumor. Joint Bone Spine 2002; 69(5): 506-10.
13. Guney E, Yigitbasi OG, Bayram F, Ozer V, Canoz O. Brown tumor of the maxilla associated with primary hyperparathyroidism. Auris Nasus Larynx 2001; 28(4): 369-72.
14. Lessa MM, Sakae FA, Tsuji RK, Filho BC, Voegels RL, Butugan O. Brown tumor of the facial bones: case report and literature review. Ear Nose Throat J 2005; 84(7): 432-4.
15. Bereket A, Casur Y, Firat P, Yordam N. Brown tumor as a complication of secondary hyperparathyroidism in severe long-lasting vitamin D deficiency rickets. Eur J Pediatr 2000; 159(1-2): 70-3.
16. Thronson RR, Sexton SB. A mandibular central lesion with unusually rapid growth. Oral Surg Oral Med Oral Pathol Oral Radiol Endod 2004; 98(1): 4-9.
17. Merz MN, Massich DD, Marsh W, Schuller DE. Hyperparathyroidism presenting as brown tumor of the maxilla. Am J Otolaryngol 2002; 23(3): 173-6.
18. Suarez-Cunqueiro MM, Schoen R, Kersten A, Klisch J, Schmelzeisen R. Brown tumor of the mandible as first manifestation of atypical parathyroid adenoma. J Oral Maxillofac Surg 2004; 62(8): 1024-8.
19. Dogan A, Algun E, Kisli E, Harman M, Kosem M, Tosun N. Calcaneal brown tumor with primary hyperparathyroidism caused by parathyroid carcinoma: an atypical localization. J Foot Ankle Surg 2004; 43(4): 248-51.

20. Scott SN, Graham SM, Sato Y, Robinson RA. Brown tumor of the palate in a patient with primary hyperparathyroidism. *Ann Otol Rhinol Laryngol* 1999; 108(1): 91-4.
21. Guimaraes ALS, Marques-Silva L, Gomes CC, Castro WH, Mesquita RA, Gomez RS. Peripheral brown tumour of hyperparathyroidism in the oral cavity. *Oral Oncol Extra* 2006; 42(3): 91-3.
22. McManus R, BoAbbas Y, Lampe H, Holliday R, Shum D. Maxillary giant cell granuloma, pheochromocytoma, and hyperparathyroidism without medullary thyroid carcinoma. *Ear Nose Throat J* 2000; 79(8): 590-3.
23. Emin AH, Suoglu Y, Demir D, Karatay MC. Normocalcemic hyperparathyroidism presented with mandibular brown tumor: report of a case. *Auris Nasus Larynx* 2004; 31(3): 299-304.
24. Yamazaki H, Ota Y, Aoki T, Karakida K. Brown tumor of the maxilla and mandible: progressive mandibular brown tumor after removal of parathyroid adenoma. *J Oral Maxillofac Surg* 2003; 61(6): 719-22.